Lap Seat Belt Injuries; The Treatment of the Fortunate Survivor

BY RICHARD C. SCHNEIDER, M.D.
WILLIAM S. SMITH, M.D.
WILLIAM C. GRABB, M.D.
JEREMIAH G. TURCOTTE, M.D.
DONALD F. HUELKE, Ph.D.
ALL OF ANN ARBOR

ABSTRACT — The lap seat belt has prevented many traffic fatalities during the past decade. With the use of this protective device, however, certain characteristic traumatic lesions have occurred in some cases. A multidisciplined approach to their treatment and the possible prevention of such injuries by a combination of the cross-chest strap and lap seat belt is presented.

This multidisciplined clinical study is from the University of Michigan Highway Safety Research Institute. The study was supported by a grant made by Alvin M. Bentley and in part by USPHS grant UI-00008 from the Injury Control Program, National Center for Urban and Industrial Health.

Much of the initial data on occupant kinematics and injury reduction has been collected from simulated accidents employing dummies or cadavers as car occupants. At our institution on-the-scene investigations of fatal automobile accidents have been conducted, correlating the fatal injuries with the objects that produced these fatalities (ejection, steering, assembly, instrument panel, etc.)[12,18,19,20] and the pathologic findings in the fatally injured.

The present review was undertaken because there are few reports available which describe the special problems of persons wearing lap belts who survive accidents. A well-coordinated, multidisciplined team of physicians should provide not only treatment for the injured in such traffic accidents, but also assemble significant clinical data for research purposes as an aid to future injury preventative measures.

LAP SEAT BELTS have been proven effective in preventing many serious and fatal injuries.[1,2,3,11,12,13,23,37,42,45,46]

However, it is possible that a new protective device preventing one type of injury or fatality may cause undue stresses in other body areas producing different traumatic lesions. Sporadic reports have appeared in the literature related to seat belt injuries[5,6,8,9,10,14,17,22,24,30,32,33,37,41,44]; the most comprehensive review being presented by Snyder, et al.[38]

At the outset it must be emphasized that this article is written not to condemn lap seat belts but to advocate them, for without these safety measures more serious injuries and fa-

CO-AUTHORS

SCHNEIDER

SMITH

GRABB

TURCOTTE

HUELKE

From the University of Michigan Medical School, Department of Surgery: Dr. Schneider, Section of Neurosurgery; Dr. Smith, Section of Orthopedic Surgery; Dr. Grabb, Section of Plastic Surgery; Dr. Turcotte, Section of General Surgery. Dr. Huelke is a member of the Department of Anatomy.

talities would occur in automobile collisions.[20,44]

The substitution of a shoulder-lap belt combination[3,13,28,34,36] for only the single lap seat belt is gradually evolving as the next step forward which the public must take to afford further protection. Indeed, one may face the possible appearance of different important sequelae with this innovation, but like the use of lap seat belts, it should not be a deterrent from a shift toward improved safety equipment. Cooperative studies by the physician, automotive engineer, and highway safety teams must continue and be expanded.

FIVE CASE REPORTS of patients with injuries from automobile mishaps are presented to illustrate certain types of lesions which may be associated with the use of lap seat belts.

Because of the specific mechanisms involved, the investigation of these principles by the team approach provides a better understanding of the type of treatment which is necessary and the best opportunity for full recovery of that patient.

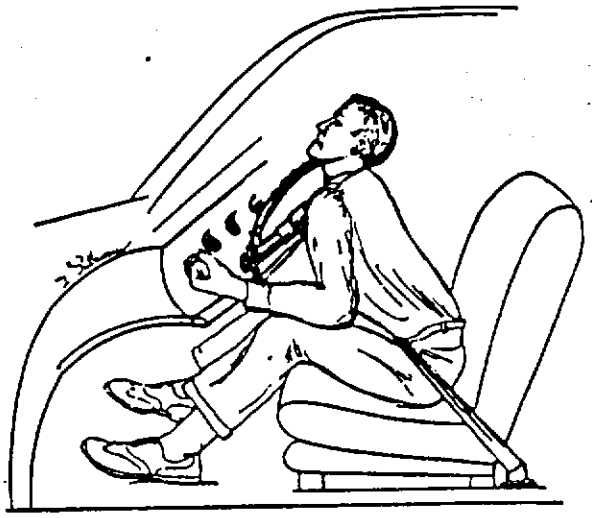

Fig. 1A:

Initially the patient sustains acute flexion of the cervical spine catching the chin on the steering wheel. The diagram demonstrates the severe hyperextension of the cervical spine, which, with the slumping of the body, provides the mechanism for the hangman's fracture.

CASE REPORTS

Cervical Spine Fracture And Vocal Cord Paralysis

Case 1:[32*] R.M., a young millworker, was admitted to the hospital on June 5, 1962, having been injured 42 hours previously in a two-car collision. He was wearing a lap seat belt. Although stunned, he was not unconscious and recalled that his head had flexed acutely forward resulting in the steering wheel catching him beneath the chin (Fig. 1A). Immediately after the injury, his respirations were very labored with stridor and supraclavicular retraction. He could not speak above a whisper, and on attempting to swallow fluids a marked retropharyngeal swelling caused him to choke. There was a complete paralysis of the right vocal cord, marked paresis of the left cord, and displacement of the left arytenoid cartilage. Roentgenograms of the cervical spine demonstrated an avulsion of the neural arch of the second cervical vertebra from its body with slight disruption of the pedicles of the third cervical vertebra (Fig. 1B). A marked degree of swelling was demonstrated in the retroesophageal area at C4, C5, and C6 vertebrae.

Traction with Crutchfield skeletal tongs was applied shortly after admission to the hospital. A tracheostomy had been performed after the accident. With the exception of the above findings, there was no neurologic deficit. Skeletal traction was continued until shortly before discharge from the hospital nine weeks after injury, and a cervical brace was instituted (Fig. 1C). At this time the tracheostomy was still necessary. Subsequent laryngeal surgery was required to restore the patient's voice.

A follow-up evaluation on November 1, 1963 showed no neurologic abnormality except for slight soreness of the musculature of the neck.

Comment: The patient was originally admitted to the neurosurgical service because of his cervical spine fracture and was treated in skeletal traction as a method of stabilization. Because of his marked retropharyngeal swelling and the con

*Reprinted courtesy Journal of Neurosurgery, XXII, No. II, 141-154, (1965)



Fig. 1 (B & C).

Fig. 1B: Lateral x-rays show an avulsion of the neural arch of the 2nd cervical vertebra with slight disruption of the pedicles of the C3 vertebra. (From Schneider et al, Journal of Neurosurgery, 22, No. 2: 141-154, 1965).

Fig. 1C: Repeat cervical spine x-rays with the patient in a brace show good realignment and some healing of the fracture.

plete paralysis of his right vocal cord and paresis of the left one, it was necessary for him to have a tracheostomy. Subsequently, the otolaryngologist performed laryngeal surgery in order to restore the patient's voice.

The patient recalled flexing his forehead downward, catching his chin over the steering wheel and throwing his neck into some hyperextension. He was wearing a lap seat belt which, no doubt, prevented him from striking other parts of the interior of the car more severely but resulted in the patient "hanging" himself on the steering wheel.

In 1965, Schneider, *et al*[32] presented eight cases of traffic accidents in which the patients sustained a fracture-dislocation of C2 and C3 vertebra with a bilateral avulsion of the laminar arches from the C2 vertebral body. This injury usually was associated with little or no neurologic deficit, and the spine healed quite readily without operation as long as adequate external fixation was provided. A well fitting four-post brace worn for ten weeks is quite adequate for these purposes. This report was made by two neurosurgeons (Schneider and Livingston) working in cooperation with two British anatomists (Cave and Hamilton). The latter had observed that this highway accident injury was similar to that seen in judicial hanging where the "drop" technique was used. The lesion itself was ably described by Wood-Jones[47] (Fig. 1D) and subsequently confirmed by other authors.[43] The mechanism for the development of "hangman's fracture" is best related by quoting from the article by Schneider *et al*[32]: ". . . not only do the joints of the atlanto-axial complex confer upon the skull the requisite range of mobility (flexion, extension, rotation) but the complex itself serves also to transmit the weight of the cranium to the unmodified portion of the cervical spinal column, which begins at the third cervical vertebra.

The junction of the cervicocranium with the (so to speak) vertebral column proper constitutes a site of mechanical weakness in the spine and

here the third cervical vertebra forms a fixed point. The application of such a disruptive force as that operative in judicial hanging will tend always to detach the cervicocranium from the rest of the vertebral column. The situation of the line of fracture in judicial hanging (through the neural arch of the axis or even through its body or through that of the third vertebra) is, therefore, understandable, particularly when the normal

Fig. 2.

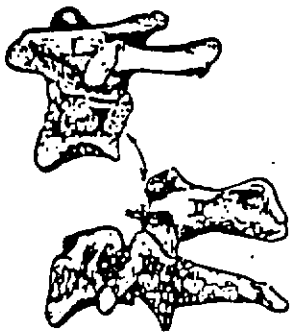

The lesion present in Captain C. P. Fraser's series of judicial hangings. Separation of the arch of the axis from the body; effect of a substantial kind.

Fig. 1D:
Reprinted from article by F. Wood-Jones[47]

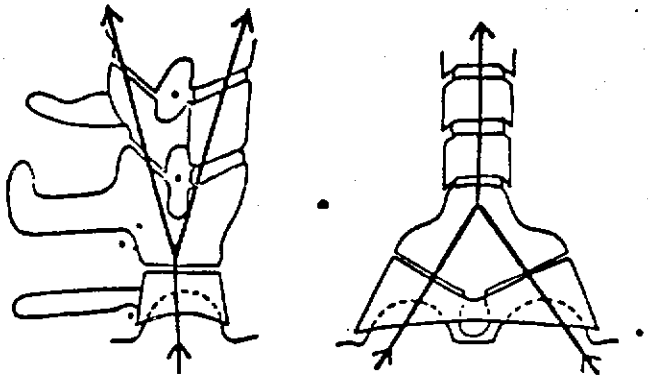

Fig. 1E:
Anterior and lateral aspects of craniocervical region to illustrate the lines of transmission of cranial weight through the atlanto-axial complex to the spinal column proper and the consequent mechanical vulnerability of the neural arch of the axis (A.J.E. Cave). (From Schneider et al, Journal of Neurosurgery, 22, No. 2: 141-154, 1965)

lines of transmission of cranial weight are appreciated (Fig. 1E). The weight of the skull and its contents is transmitted bilaterally through the occipital condyle, the lateral mass of the atlas, and the superior articular process of the axis, the two lines uniting in the body of the axis caudal to the base of the odontoid process. Thence, weight is transmitted farther caudally along three distinct lines, namely along the line of the vertebral bodies and discs medianly and along the line of the pre- and post-zygapophyses bilaterally. These three lines of transmission diverge from the focal point in the body of the axis already mentioned, each of the lateral lines passing through the weakest point of the neural arch of the axis which is thus predisposed to rupture in a hangman's fracture, however induced. Naturally, the sequelae of hangman's fracture can be studied only in victims of traffic accidents who have sustained such a fracture and yet have survived."

Perhaps some of these neck fracture patients sustain their injuries on the steering wheel or, in a similar fashion, by "hanging" themselves on the instrument panel with severe hyperextension of the cervical spine and the downward jerk of the body as it flexes forward to the floor of the vehicle.

Lumbar Spine Fracture-Dislocation And Perforation of Small Bowel

Case 2: This nine-year old, right handed girl, was involved in an automobile accident on March 4, 1966. She was thrown forward striking her head against the right side of the instrument panel rendering her transiently unconscious. This occurred in spite of the fact that she was wearing a lap seat belt. It should be emphasized that the seat belt was somewhat loosely applied. She had a headache and lower back pain. Her vital signs were normal and her pupils were equal and active. There was bilateral periorbital ecchymosis which was more marked around the left eye. She had bilateral abrasions and ecchymosis over the iliac crest and the inguinal ligaments (Fig. 2A). With the exception of the marked spasms of the abdominal musculature, originally attributed to spinal cord injury and abdominal wall contusion, there were no neurologic findings.

X-rays of the skull demonstrated a linear left frontal skull fracture (Fig. 2B). The lumbar spine films demonstrated a distraction fracture-disloca-

tion at the L2-L3 intervertebral space with a mild compression fracture of the L3 vertebral body (Figs. 2C and 2D).

The patient was treated initially with bed rest only. Her abdominal signs disappeared and she began eating normally. Thirteen days following her injury the surgical intern noted increasing right lower quadrant tenderness. Subsequently,

Fig. 2A.
The photograph taken a week after injury shows bilateral periorbital ecchymosis, a laceration at the left angle of the mouth, and bilateral abdominal abrasions above both iliac crests in the inguinal regions anteriorly.



Fig. 2B.
The skull x-ray demonstrates the left linear frontal fracture.

she became nauseated and vomited intermittently. The WBC rose to 13,500 and a flat plate and upright x-ray of the abdomen were compatible with bowel obstruction. General surgical consultation was obtained and operation was advised. At operation a point of nearly complete obstruction of the distal ileum 10 inches proximal to the ileocecal valve was found. The ilium had been injured on its mesenteric border in two adjacent areas. The obstruction was caused by a combination of scarring and adhesions of nearby loops of bowel to the site of injury. Ten inches of small bowel were resected (Turcotte) and continuity was re-established by an end-to-end anastomosis. Two-hundred ml of sterile serous fluid was aspirated from the peritoneum. Pathologic examination of

the resected bowel demonstrated a probable site of perforation which subsequently sealed. On April 5, 1966, the orthopedic surgeon (Smith) exposed the spinal distraction fracture-dislocation site and found rupture of the interspinous ligament, rupture of the capsular ligament of the facets, rupture of the ligamentum flavum and complete dislocation of the facets. The L2-L3 interspinous distance was approximately twice normal. These spinous processes were wired together and a spinal fusion was performed using an iliac bone graft. Post-operative x-rays of the lumbar spine showed almost complete correction of the deformity (Figs. 2E and 2F). She was placed in a body cast and discharged from the hospital on April 21, 1966. At this time she was neurologically negative and asymptomatic.

Comment: This little patient had a combination of cranial, spinal, and abdominal injuries, possibly due to the fact that her seat belt was not properly tightened.[1,37] Nevertheless, this restraint very likely kept her from striking her chest and abdomen against the instrument panel, the object most frequently struck in front right passenger fatalities.

Fortunately, the skull fracture was merely a linear one in the frontal area. It was uncomplicated by any intracranial traumatic lesion. Smith and Kaufer[37] have shown that while a myriad of lesions is produced in belted individuals the only lesion that is unique to seat belt (lap) users is the pattern of the mid-lumbar spine injuries. Unlike any other lumbar spine injury it is characterized by:

1) Rupture of the interspinous ligaments, consequently widening of the interspinous space.

2) Rupture of the capsular ligaments of the facets.

3) Complete rupture of the ligamentum flavum.

4) Marked widening of the intervertebral foramina.

5) Minimal compression of the anterior-most part of the lower vertebral body, or a variation of the pattern, the chief of which is a fracture extending horizontally through the body, the pedicle, the transverse process and the spinous processes.

This pattern has been duplicated twenty-one times in this series. The lap seat belt modifies

Fig. 2 (C & D).
Fig. 2C. Lumbar spine x-rays demonstrate the degree of distraction at L2-L3 and L3-L4 intervertebral spaces. This is well illustrated by the arrows adjacent to the distorted spinous processes.
Fig. 2D. The lateral view of the lumbar spine demonstrates the enlargement of the L2-L3 intervertebral foramen due to distraction of the joints.

Fig. 2 (E & F).
These x-rays show the reapproximation of the L2 and L3 spinous processes and the stabilization of the lumbar spine by the wiring and spinal fusion which was performed.

the collision forces in such a way as to be a significant factor in the production of this unique lumbar spine injury.

Neither the skull fracture nor the distraction-fracture of the spine was associated with neurologic deficit. The abraded skin across the groin bilaterally is a typical lap seat belt contusion.[9] The child's initial abdominal signs were probably due to a combination of contused abdominal wall and a contused or perforated bowel. Although spinal cord injuries may be associated with a paralytic ileus, a fracture-dislocation at the L2-L3 interspace could not account for the rectus muscle spasm. A spinal cord injury at this level would manifest itself by neurologic signs in the lower extremities, and not in the trunk or abdomen. The signs which appeared two weeks after injury were due to intestinal obstruction. Alertness of the surgical intern in detecting these signs and the prompt surgical treatment allowed complete recovery from this injury. Surgeons should be aware that injuries severe enough to contuse the abdominal wall may also contuse intra-abdominal viscera. This may lead to delayed perforation, scarring, hemorrhage, or intramural hematoma formation in bowel. Other cases of lap seat belt injuries associated with ruptured viscera have been been reported.[5,9,22,41]

A comprehensive review of the various seat belt injuries has been presented by Snyder *et al.*[38]

Fractures of Roofs of Both Orbits And the Naso-orbital Region

Case 3: I.S., a small forty-one year old, right handed housewife, was occupying the front passenger seat in an automobile which was involved in a head-on collision on December 14, 1966 (Fig. 3A). The resulting damage was photographed by the anatomist (Huelke). The patient's husband, who did not have his seat belt fastened, struck the windshield (Fig. 3B) and sustained lacerations and bruises of his face and scalp. He was not rendered unconscious. His wife had her lap seat belt fastened but nevertheless struck her head on the edge of the instrument panel (Figs. 3C thru 3F). She did not lose consciousness. Upon examination her blood pressure was 170/100 and her pulse was 88 per minute. There was a bloody serous fluid exuding from both nostrils. She had a 4-centimeter laceration medial to the right eye, but her



Fig. 3A.

The result of the head-on collision in which the patient was injured is shown.



Fig 3C.

The patient, riding in the guest passenger seat and wearing a seat belt, was thrown forward so that his head struck the unpadded and unyielding instrument panel. Only smudge marks on the edge of the instrument panel indicated the point of impact.

Fig. 3B.

The driver, who was not wearing a seat belt, struck the windshield with his head. The point of impact is at the center of the 'spider web' of shattered glass, while the point where he sustained his lacerations is about six inches below. This downward arcing of the head thus accounts for the slicing lacerations so commonly seen in accident victims striking the old type of windshield glass.[21] (Since 1966 American model cars have used a new improved windshield which markedly reduces the frequency and severity of facial lacerations).

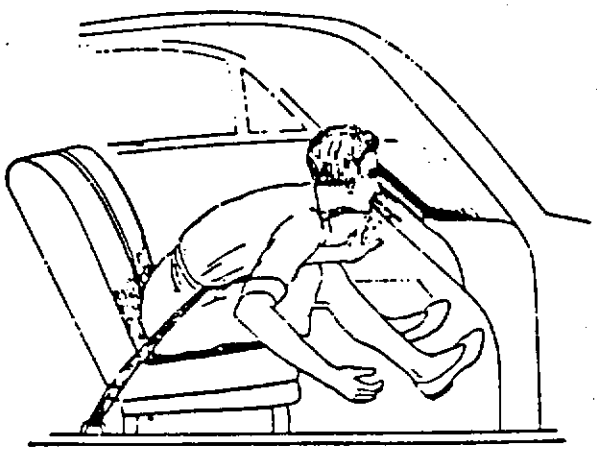

Fig. 3D.

The acute symmetrical blow of the head against the dashboard is shown with considerable hyperextension of the neck. Note the restraining action of the seat belt with the associated flexion of the lumbar spine. This type of pattern is especially true for small occupants. Taller individuals will strike the top of the instrument panel.

Fig. 3 (E & F).
The anterior and lateral view exhibit the compound fracture of the nose and marked inward displacement of the nasal bone.



Fig. 3 (G & H).
Fig. 3G: The lateral view of the nose shows the comminuted depression of the nasal bone. The paper-thin bones (lacrimal bone and lamina papyracea of ethmoid bone) which make up the medial wall of the orbit have also been fractured and displaced backward.
Fig. 3H: The fracture of the cribriform plate is demonstrated anteriorly.

pupils were equal and reacted to light. A subconjunctival hemorrhage was noted in the right eye and the extraocular movements impaired in all directions; the right pupil was 2 millimeters larger than the left. The remainder of her neurologic examination was normal.

Skull x-rays showed pneumocephalus and demonstrated the depressed comminuted compound fracture at the nasion (Fig. 3G) with fractures of the roof of both orbits as well as fractures of the right zygoma, nasal bones, and medial walls of both orbits (Fig. 3H).

A transcoronal incision was made and a bifrontal craniotomy based on a right temporal muscle flap was performed by the neurosurgeon (Schneider). The inner table of the frontal region had been avulsed from the outer table bilaterally as a solid piece (en bloc) carrying with it

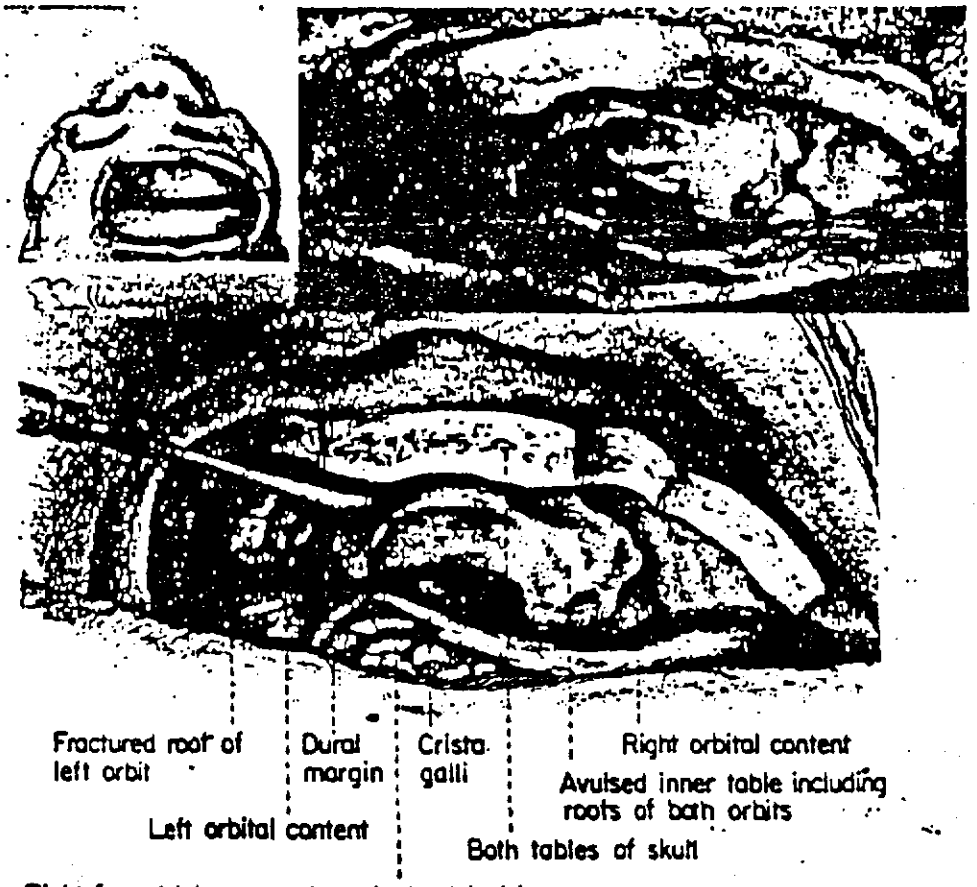

Fig. 3I.

Insert top, left: Site of craniotomy exposure.

Insert top, right: Actual photograph of site of "en bloc" avulsion of inner table of frontal bone bilaterally including cribriform plate, crista galli and the roof of both orbits (dotted line).

Lower diagram: This drawing identifies the structures at the site of the lesion seen in the photograph above.

Fig. 3 (J & K)
The patient is seen five months postoperatively with the nasal bones in their normal position.

the crista galli and the anterior portions of the roofs of the orbit bilaterally (Fig. 3I). The inner and outer bone tables were wired together. The posterior orbital roof was completely morcellated bilaterally and had to be excised piecemeal. Four lacerations in the dura could be readily closed by simple suture. When these suture lines were tested by the injection of indigo carmine intradurally, the dura was watertight. The plastic surgeon (Grabb) then repaired the facial lacerations and performed an open reduction and internal wire fixation of the nasal fractures. The patient received triple antibiotic therapy and made an uneventful recovery. She was discharged on December 30, 1966, with slight diplopia on left lateral gaze.

Five months postoperatively at a return visit she was mentally alert, asymptomatic, and had obtained a good cosmetic result (Figs. 3J and 3K).

Comment: In this accident the driver was not wearing his lap seat belt and was thrown forward over the steering wheel striking the windshield with his face. The lacerations which he sustained were typical of those occurring by downward head movement with the face passing through the glass as has been described by Huelke, Grabb, and Dingman.[21] The point of impact in this accident was head-on, more in line with the front guest passenger; the driver was somewhat protected by the steering wheel.

In the case of his wife, who was in line with the impact, the seat belt undoubtedly saved her life but nevertheless she struck her head on the unpadded and unyielding instrument panel. Externally the most striking feature of her injury was a markedly depressed naso-orbital fracture, the extent of which was confirmed by the x-ray examination. She also had bilateral bloody cerebrospinal fluid rhinorrhea indicating communication with the subarachnoid space. If such drainage is permitted to continue untreated surgically, the result may well be future chronic bouts of men-

ingitis, or brain abscess and subsequent death.[21]

In this case the skull fracture was unique in that the entire inner table of the skull, including the crista galli and the roof of both orbits was avulsed completely and almost symmetrically, en bloc, as a single huge fragment of bone.

Although there were multiple bony fragments at the posterior portion of the orbits, fortunately there was no damage to the orbital contents. This has not been the usual experience of the neurosurgeon who has repaired approximately 75 such post-traumatic frontal cerebrospinal fluid fistulae. The orbit is often injured, the optic nerve may be avulsed, and usually the cribriform plate buckles in such fractures with several bony spicules lacerating the dura and occasionally penetrating and becoming imbedded in the brain.[20] Such dural lacerations are frequently associated with large dural defects and usually require a dural graft. In the case here reported there were only four linear dural lacerations without any loss of this tissue so watertight closure could be obtained by simple interrupted black silk sutures. The lack of avulsion of the dura can be accounted for by the massive single bony fracture. Such an en bloc fracture of the skull probably requires a direct symmetrically applied blow to the base of the nose. This case supports two old neurosurgical adages:

1. There is always 100 per cent more damage to the skull visualized intracranially at operation than is seen in the preoperative skull x-ray of the patient with this type of fracture.
2. Some of the worst skull fractures often are associated with little or no brain damage, for there is a dissipation of force instead of the direct force transmission to the brain.

Dingman, *et al*[7] have urged the early reduction and fixation of this type of nasal fracture to prevent chronic facial deformity or disfiguration. The excellent cosmetic result attained in this patient supports this dictum and demands that it receive further active support.

Facial Laceration And Back Strain

Prevention of severe facial and intracranial injuries from head impact can be accomplished by adequate instrument panel design in the head impact areas. This is illustrated in the following case:

Case 4: Two women, both short of stature, were driving with the front seat moved well forward. Both were wearing the lap seat belts. The car was forced off the road; it struck a tree at 20-25 m.p.h. The impact was to the center front of the car. The passenger flexed over her belt and struck the unpadded instrument panel with her face (Fig. 4). Besides bilateral periorbital ecchymosis, she had a hairline fracture of her left maxilla. An "L" shaped laceration between her eyebrows was sustained when she struck the corner of the radio grille which did not deform with the instrument panel. Her main complaint was a sore back. She had stretched the vertical deep back muscle group from the coccyx to the upper lumbar area. At the time of the accident her seat belt was worn high,



Fig. 4
Facial impact of a seat belted passenger onto an unpadded instrument panel. The occupant sustained a hairline fracture of the left maxilla, an "L" shaped laceration between the eyebrows from the edge of the radio grille. Stretching of the deep back muscles in the lumbar area was the main complaint of the patient.

above the iliac crests, and she had on a "substantial" foundation garment. Several weeks later her back problem resolved itself without clinical treatment.

Comment: In this case the instrument panel deformed, dissipating the impact energy. It is this type of instrument panel response to head impact that is required for the seat belted occupant. Padding over this deformable metal panel would have spread the impact load over a wider area and possibly prevented most of her facial injuries. The seat belt not being worn properly and the possible restraining effect of her foundation garment prevented adequate flexion over the belt, causing severe strain of the deep back muscles.

Brachial Plexus Involvement

Case 5: A young driver, who had lost his license due to numerous driving violations, lost control of the car on a curve, crossed the center line, and struck another car. Both vehicles struck right front to right front. The driver at fault was not wearing a seat belt. He struck his head on the right side of the instrument panel and died of intracranial injuries.



Fig. 5
Collapse of the steering wheel by a seat belted 230 pound male driver. Minor facial lacerations and a sore chest were sustained from wheel impact. His right shoulder struck the instrument panel producing a stretching of the brachial plexus roots and partial loss of shoulder joint function for six months.

The sixty-two year old 230 pound male driver of the other car was wearing a lap seat belt. He flexed over the seat belt and collapsed the steering wheel sustaining a sore chest and facial lacerations (Fig. 5). His right shoulder had struck the instrument panel and he had suffered marked paresis of the right deltoid, supraspinatus and infraspinatus muscles with slight weakness of the right triceps and biceps muscles and a minimal hypesthesia over the C4 dermatome. There were compression fractures of the T9 and T10 vertebrae with paravertebral hemorrhage, a fracture of the right acetabulum, the right inferior ramus of the pelvis, a fracture of the radial head of the right elbow, a trimalleolar fracture of the right ankle, fractures of the left zygoma and the right maxillary sinus.

The patient was in traumatic shock at the time of admission to the hospital. After this had been treated a general surgeon sutured the facial lacerations including a transected parotid duct. The trimalleolar fracture was reduced and stabilized by internal fixation and the fracture of the right elbow placed in a cast by the orthopedic surgeon. The neurosurgical consultant reviewed the symptoms referable to the right upper extremity and made a diagnosis of brachial plexus stretch injury which was treated by support and physiotherapy. The patient's course was one of continued improvement with discharge from the hospital six weeks after the injury.

Comment: In this severe accident the unbelted driver of the one car moved out of his position behind the wheel to sustain fatal injuries when he struck his head on the right side of the instrument panel. On the other hand the belted elderly driver of the second vehicle survived although he had multiple injuries which were rather successfully treated by a team of surgeons. In this case the lap seat belt no doubt saved the patient's life.

DISCUSSION

The multidisciplined approach to the care of highway injuries not only provides a better treatment for the patient but reveals some interesting

lesions possibly related to the use of lap seat belts: the hangman's fracture (Case 1), the distraction fracture of the lumbar spine (Case 2), injury to the abdominal viscera (Case 2), and the "en bloc" fracture of the inner table of the skull and naso-orbital region (Case 3).

DeHaven, *et al*[6] have pointed out that injuries which seem directly related to the lap seat belt "are actually determined by other factors such as a failure of safety belt installations and vertical acting crash forces." Garrett and Braunstein[14] studied the "seat belt syndrome" in 3,637 occupants of 2,778 accident-involved automobiles and found 150 of these people had received an injury to the lower torso. Of these, twenty-six injuries were regarded as serious, consisting of intra-abdominal injuries (7), pelvic fractures (7), and lumbar spine fractures (12); but the majority of these people were in very severe accidents. These authors were able to find only a single case of a fatal lower torso injury in this group, thus demonstrating the effectiveness of the lap seat belts. Greater lap belt snugness by inertia reels[22] might have afforded increased protection in Case 2.

THE LIMITATIONS OF seat belts have also been recognized.[23] The single upper torso restraint is highly undesirable, for without an accompanying lap seat belt the passenger slides out underneath such a harness (submarines) and is liable to added injury such as fractures or dislocations of the cervical or thoracic spine.[12,15] When the three point system is used in which the diagonal strap is joined to the lap belt, there is a tendency for the lap belt to be pulled upwards onto the soft abdominal wall. It has been recommended that the lap and shoulder belt be separate (Fig. 6), for this combination does not have the undesirable characteristics of the other systems mentioned above. Such a double, independent belt system will still offer lap belt protection for those who for some reason will not wear the shoulder belt. A lap-shoulder belt combination (Fig. 6) would very likely have offered sufficient upper torso restraint in all cases so that it is doubtful whether the chin would have been caught upon the steering wheel (Case 1) or the head impacted against the dashboard as occurred in the other cases. The importance of available "cabin space" has been emphasized by Huelke and Gikas; for when there is collapse and compromise of the cabin area, the value of any restraint system is negated.[20] There

Fig. 6
Lap-shoulder belt combination. Note individual buckles for the lap and for the shoulder belts.

is a definite need for an adequate child restraint system.

It is possible that restraining the pelvis and upper torso by the use of the lap and shoulder belts may occasionally permit the cervical spine to be snapped at the time of forward impact in rear end collisions. Hyperextension of the cervical spine can be prevented by the use of a head support. It is possible that if such a head restraint is not adequately designed, the head and neck could sustain a severe blow as they swing back and strike the head support. Since there is a certain degree of inertia of the intracranial contents, the brain could rebound forcibly forward striking the frontotemporal junction against the sharp margins of the sphenoid ridges with possible cerebral contusions or lacerations to the frontotemporal junction resulting in an intracerebral clot.

Recently a car was struck in the rear and pushed through a bridge railing. It fell 100 feet to the ground into the yard of a foundry at an estimated speed of 53 m.p.h. The car landed on its rear end. The driver, a thirty-four year old, 270-pound male, was not wearing seat belts but did have a head support. He claimed he held tightly to the steering wheel during the fall and probably had his head on the head support. He was not unconscious and did not complain of any

neck pain. His only injury was a fracture of the right humerus.[20] Time and careful clinical examinations will provide the answer as to whether such a specific safety feature could possibly cause serious injuries when the head is not in direct contact with the head support.

SUMMARY

Case histories of five automobile accident survivors have been presented in detail. Each of these individuals wore a lap seat belt the use of which in most cases probably saved the occupant's life.

Emphasis has been placed on the treatment of these patients by a coordinated multidisciplined team which helped them recover, but in so doing the team also noted new types of injuries related to the lap seat belt restraint.

The findings of this study suggest that although the patients' lives were saved, the further advance of lap and shoulder belts might have provided additional protection and completely prevented any serious injury.

REFERENCES

1. American Academy of Pediatrics. Committee on Accident Prevention. Report: Seat Belts in Prevention of Automobile Injuries. Pediatrics 30:841-843. (1962).
2. *Campbell, H. E.* Role of the Safety Belt in 19 Auto Crashes. Bulletin American College of Surgeons 50:155 (1955).
3. *Campbell, H. E.* And Shoulder Strap. Too. Editorial. Rocky Mountain Medical Journal. January (1963).
4. *Clark, C. and Blechschmidt, R.* Human Transportation Fatalities and Protection Against Rear and Side Crash Loads by the Airstop Restraint. Proceedings of the Ninth Stapp Car Crash Conference. University of Minnesota. (1966). pp. 19-64.
5. *Cocke, W. M. and Meyer, K. K.* Splenic Rupture Due to Improper Placement of Automobile Safety Belt. Journal of American Medical Association. 188:693. (February 23. 1963).
6. *DeHaven, H., Tourin, B. and Macri, S.* Aircraft Safety Belts. Their Injury Effect on the Human Body. Crash Injury Research of Cornell University Medical College, New York, July. (1953).
7. *Dingman, R. O., Grabb, W. C. and O'Neal, R. M.* Nasal and Naso-orbital Fractures. Plastic and Reconstructive Surgery (In press).
8. *Engberg, A.* Injuries Caused by Safety Belts. A Contribution to the Discussion with Reference to an Unusual Case. Svenska Lakartidningen 58:884-886. (1961).
9. *Fish, J. and Wright, R. H.* The Seat Belt Syndrome. Does It Exist? Journal of Trauma 5:746-750. (1965).
10. *Fletcher, B. D. and Brogdon, B. G.* Seat-belt fractures of the spine and sternum. Journal of American Medical Association. 200:167-168. (April 10. 1967).
11. *Frazier, R. G.* Effectiveness of Seat Belts in Preventing Motor Vehicle Injuries. New England Medical Journal. 244:1254-1256. (1961).
12. *Fredericks, R. H.* Barrier Collision Investigation of Harness Restraining Systems. Proceedings of the Seventh Stapp Car Crash Conference. Charles C Thomas. Publisher. Springfield. Illinois (1965). pp. 1-17.
13. *Ganslen, R. V.* Human Tolerance to Automatic Restraint Harness Activator Forces Proceedings. The Ninth Stapp Car Crash Conference. University of Minnesota. (1966) pp. 13-18.
14. *Garrett, J. W. and Braunstein, P. W.* The Seat Belt Syndrome. Journal of Trauma 2:220-238. (1962).
15. *Gikas, P. W. and Huelke, D. F.* Causes of Death in Automobile Accidents. Can Seat Belts Really Save Lives? Journal of Michigan State Medical Society. 63:351-354. (1964).
16. *Gikas, P. W. and Huelke, D. F.* Pathogenesis of Fatal Injuries to Rear Seat Occupants of Automobiles. Proceedings of the Ninth Stapp Car Crash Conference. University of Minnesota. (1965). pp. 355-361.
17. *Herbert, D. G.* Injury Reduction by Diagonal and Other Vehicle Safety Belts. Medical Journal of Australia. 1:61-72. (January 18. 1964).
18. *Huelke, D. F., Gikas, P. W. and Hendrix, R. C.* Patterns of Injury in Automobile Accidents: A Review of 231 Autopsy Cases. The Sixth Stapp Car Crash Conference Proceedings. University of Minnesota. (1962).
19. *Huelke, D. F. and Gikas, P. W.* How Do They Die? Medical Engineering Data from On-Scene Fatal Automobile Accidents. SAE Paper No. 1003A: Detroit Meetings. January. (1965).

20. *Huelke, D. F. and Cikas, P. W.* Determination of Seat Belt Effectiveness for Survival in Highway Collisions. The Seventh Stapp Car Crash Conference Proceedings, Charles C Thomas, Springfield, Illinois (1965).

21. *Huelke, D. F., Grabb, W. C. and Dingman, R. O.* Facial Injuries due to Windshield Impacts in Automobile Accidents. Plastic and Reconstructive Surgery 37:324-333, (1966).

22. *Kulowski, J. and Rost, W. B.* Intra-abdominal Injury from Safety Belt in Auto Accident. Report of a Case. Archives of Surgery 73:970:997, (December 1956).

23. *Lindgren, S. and Warg, E.* Seat Belts and Accident Prevention. The Practitioner 188:467-473, (April 1962).

24. *Lister, R. D. and Milson, B. M.* Car Seat Belts — an Analysis of the Injuries Sustained by Car Occupants. The Practitioner, 191:332-340 (September, 1963).

25. *Michelson, I. and Tourin, B.* Consumers Union Dynamic Tests of Seat Belts. Proceedings of the Fifth Stapp Automotive Crash and Field Demonstration Conference, (1961), pp. 243-248.

26. *Moreland, J. D.* Safety Belts in Motor Cars, an Assessment of Their Effectiveness. Ann. Occup. Hyg., 5:95-111 (April-June, 1962).

27. *Neff, R. J.* A Report on Consideration of Seat Belts for Infants and Small Children. The Fifth Stapp Automotive Crash and Field Demonstration Conference, University of Minnesota, (1962), pp. 249-252.

28. *Provost, E. L. and Schrum, D. J.* Dynamic Research of Upper Torso Restraints. Proceedings of the Ninth Stapp Automotive Crash and Field Demonstration Conference, University of Minnesota, (1966), pp. 83-92.

29. *Rodriguez, R.* Personal Communication, Aug. 1967.

30. *Schneider, R. C.* Craniocerebral Trauma. Chapter 20, pp. 275-326. Correlative Neurosurgery. Charles C Thomas, Publisher, Springfield, Illinois (1955).

31. *Schneider, R. C. and Thompson, J. M.* Chronic and Delayed Traumatic Cerebrospinal Rhinorrhea as a Source of Recurrent Attacks of Meningitis. Annals of Surgery, 145, No. 4, 517-529 (1957).

32. *Schneider, R. C., Livingston, K. E., Cave, A. J. E. and Hamilton, G.* "Hangman's Fracture" of the Cervical Spine. Journal of Neurosurgery, 22, No. 2, 141-154, (1965).

33. *Schneider, R. C.* Traumatismos de la Columna Vertebral y la Medula Espinal. Ano. 6:1, (November 28, 1966).

34. *Sharp, J. E.* Consideration for a Lap Belt - Shoulder Harness Assembly. The Fifth Stapp Automotive Crash and Field Demonstration Conference. University of Minnesota, (1962).

35. *Sharp, J. E.* Problems with the Three-Point Belt Installations and Possible Solutions. Proceedings of the Seventh Stapp Car Crash Conference. Charles C Thomas, Publisher, Springfield, Illinois (1965) pp. 155-158.

36. *Sharp, J. E., Campbell H. E., and Utans, P.* Analysis of Lap Shoulder Belt Effectiveness in Accidents. Proceedings of the Ninth Stapp Automotive Crash and Field Demonstration Conference. University of Minnesota (1966), pp. 65-81.

37. *Smith, W. S. and Kaufer, H.* A New Pattern of Spine Injury Associated with Lap-Type Seat Belts: A Preliminary Report. University of Michigan Medical Center Journal, 33:99-104, (May-June, 1967).

38. *Snyder, R. G., Crosby, W. M., Snow, C. C., Young, J. W. and P. Hanson.* Seat Belt Injuries in Impact. The Prevention of Highway Injury Conference, Highway Safety Research Institute, The University of Michigan, pp. 188-210, 1967. (In press)

39. *States, J. D. and Benedict, J. F.* Safe and Unsafe Upper Torso Restraints for Occupant Protection in Motor Vehicles. Proceedings of the Seventh Stapp Car Crash Conference. Charles C Thomas, Publisher, Springfield, Illinois (1965). pp. 312-323.

40. *Stonex, K. A.* Discussion of "Barrier Collision Investigations of Harness Restraining Systems" (Fredericks). Proceedings of the Seventh Stapp Car Crash Conference. Charles C Thomas, Publisher, Springfield, Illinois. (1965). pp. 18-19.

41. *Tolens, S. H.* Unusual Injury Due to Seat Belt. Journal of Trauma 4:397-399, (May, 1964).

42. *Tourin, B.* Ejection and Automobile Fatalities. Public Health Report, 73:381-91, (May, 1958).

43. *Vermooten, W.* A Study of the Fracture of the Epistropheus Due to Hanging with a Note on the Possible Causes of Death. Anatomical Record 20: 305-311, (1921).

44. *Von Bahr, V. and Eriksson, E.* Injuries Caused by Safety Belts. Svenska Lakartidningen 58:141-145, (1961).

45. *Vulcan, A. P.* Review of the Relative Merits of Various Types of Motor Vehicle Seat Belts. Journal Australian Road Board. 2:33-40, (June, 1966).

46. *Wolf, R. A.* Control of Ejection in Automobile Accidents. Journal of American Medical Association 158:220-224 (April 21, 1962).

47. *Wood-Jones, F.* The Ideal Lesion Produced by Judicial Hanging. Lancet 1:53 (1913).